

## Case Report

# Effectiveness of Late Line Palliative Chemotherapy by Specialised Approach to Cancer of Unknown Primary: A Case Report

**Itaru Sato, Naoki Nakaya, Yoko Obara, Natumi Kurosaka, Souichirou Ueno, Hideo Nakajima**

Department of Medical Oncology, Ageo Central General Hospital, Ageo, Japan

### Email address:

satoi@ach.or.jp (I. Sato)

### To cite this article:

Itaru Sato, Naoki Nakaya, Yoko Obara, Natumi Kurosaka, Souichirou Ueno, Hideo Nakajima. Effectiveness of Late Line Palliative Chemotherapy by Specialised Approach to Cancer of Unknown Primary: A Case Report. *Journal of Cancer Treatment and Research*. Vol. 8, No. 4, 2020, pp. 79-81. doi: 10.11648/j.jctr.20200804.13

**Received:** November 20, 2020; **Accepted:** December 4, 2020; **Published:** December 11, 2020

---

**Abstract:** Background: Cancers of unknown primary (CUPs) are defined as histologically confirmed metastatic tumours whose primary site cannot be identified during standard pretreatment evaluation. No specific regimen can be recommended as standard of care. Taxanes and platinum-based regimens are commonly used in the first-line treatment of CUPs, but there is no specific regimen for after second-line treatment. In general, late line chemotherapy is not recommended, but we experienced a rare case of CUPs with disseminated disease that showed improvement with fifth-line palliative chemotherapy by specialised approaches based on the reconsideration of histologic type of cancer. We report a rare case in which palliation was achieved by late line chemotherapy based on pathological review. Case: The case was a 65 year-old man. Transverse colectomy and peritoneal metastasectomy were performed for CUPs. The chemotherapy was continued for 3 years afterwards, and the fourth treatment was not effective. The pathological reexamination was carried out in examining the 5th line treatment, and the chemotherapy (pazopanib) was started under the diagnosis of epithelioid sarcoma. The tumor did not shrink, but the antipyretic effect on tumor fever was achieved, resulting in palliation of symptoms. Conclusions: In general, late line chemotherapy for CUPs is not recommended, but palliative chemotherapy based on pathologic profile may be effective and relieve symptoms of CUPs.

**Keywords:** Cancers of Unknown Primary, Late Line Palliative Chemotherapy, Specialised Approaches

---

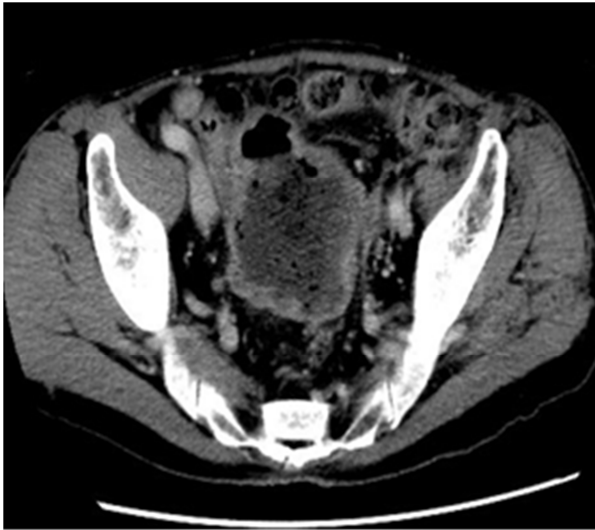
## 1. Introduction

Cancers of unknown primary (CUPs) are defined as histologically confirmed metastatic tumours whose primary site cannot be identified despite sufficient diagnostic evaluation and patients with disseminated diseases have poor prognosis. [1, 2] CUPs are heterogenous and have a wide variety of clinical presentations [3]. Poorly differentiated or undifferentiated occult primary tumours are highly responsive to platinum-based combination chemotherapy [4, 5] but there is no specific regimen for after second-line treatment. It is unclear whether late line chemotherapy provides benefits. Here, we report a case of CUPs with disseminated disease that showed improvement with fifth-line palliative chemotherapy by specialised approaches based on the reconsideration of histologic type of cancer.

## 2. Case Report

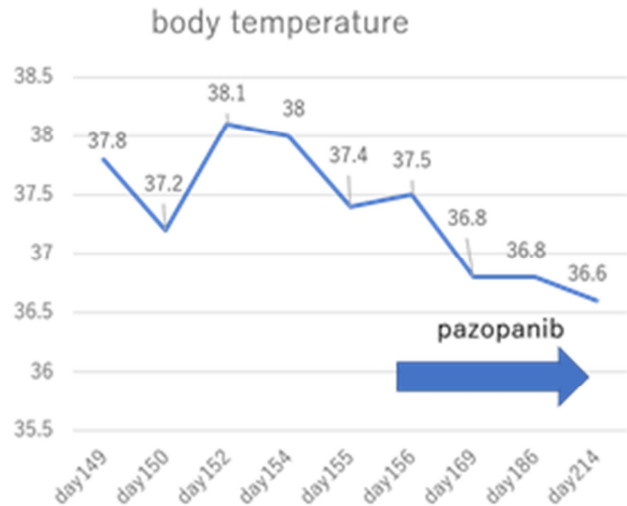
In March 2014, a 65-year-old man underwent surgery for peritoneal dissemination and transverse colon resection at hospital A, the primary site could not be identified. Undifferentiated occult primary tumours were confirmed, paclitaxel and carboplatin were administered for four cycles, and he underwent follow-up examination. In March 2015, the patient relapsed and transferred to hospital B and received chemotherapy with paclitaxel, gemcitabine and carboplatin for 14 cycles and oral etoposide. In October 2016, he was admitted to our hospital. Abdominal computed tomography (CT) showed 40.2 × 55.9 mm soft-tissue mass on dorsal side of descending colon and numerous peritoneal metastases. We continued to administer oral etoposide. 80 days after his first

visit, his disease progressed. Median survival with CUPs is 6–9 months [6]. Three years passed since the diagnosis, indicating little benefit from continuing chemotherapy. We recommended him to stop chemotherapy but he hoped to continue chemotherapy, so S-1 was administered for one cycle. 133 days after his first visit; pelvic mass grew and air was found in the tumour (Figure 1).

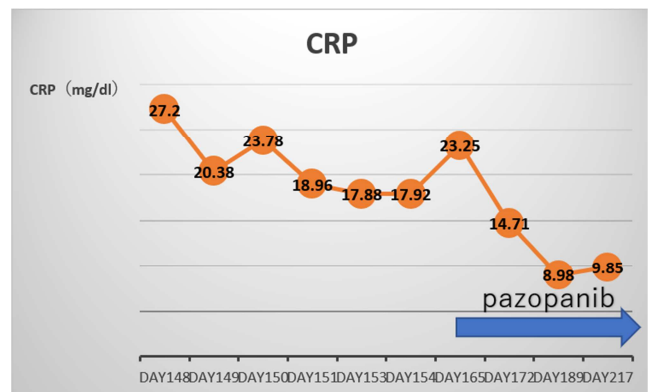


**Figure 1.** The small intestine is incontact with the tumor. Air can be found in the tumor.

143 days after his first visit, laparoscopic examinations revealed peritoneal dissemination on the abdominal wall and small intestine and tumour adherence to the sigmoid mesentery and the pelvic floor. We performed bypass small bowel to ascending colon. The postsurgical course was uneventful, but fever was prolonged. Meropenem hydrate (MEPM) administration was initiated but could not alleviate the fever. Blood cultures were negative multiple times. Research indicates that cause of fever in cancer patients is predominantly infection (60%) and non-infection (40%) [7]. Chest and abdominal CT and echocardiography did not show signs of infection and drug fever and deep vein thrombosis. Chang advocated diagnostic criteria for tumour fever [8]: fever  $\geq 37.8$  degrees once a day or more, fever longer than two weeks, exclusion of infection, denial of allergy, no reaction to empiric antimicrobial therapy of  $\geq 7$  days, antipyretic by naproxen. This case met five of the above criteria the patient was diagnosed with tumour fever. We recommended BSC to him again, but he continued chemotherapy. Hospital A provided detailed pathological results and we reviewed the chemotherapy regimens. Immunostaining showed that the tumour was positive for AE1/3 and vimentin and negative for S-100. Morphological findings and immunostaining confirmed the diagnosis of epithelioid sarcoma. We decided to administer pazopanib. 168 days after his first visit, he received pazopanib (600 mg/day) orally every day, and his body temperature dropped and CRP declined from 23.25 to 8.98 mg/dl 170 days after his first visit (Figures 2 and 3).



**Figure 2.** Changes in body temperature after starting pazopanib.



**Figure 3.** Transition of CRP after starting pazopanib.

We reduced pazopanib dosage to 400 mg/day on day 192 and 200 mg/day on day 222 due to diarrhoea. Abdominal CT on day 232 after his first visit showed no change in pelvic mass size, so he continued pazopanib and symptoms were eventually alleviated.

### 3. Discussion

According to the Practical Guidelines for Carcinoma of Unknown Primary, 2<sup>nd</sup> Edition Japanese Society of Medical Oncology, whether or not to continue secondary and tertiary chemotherapy should carefully be determined by the patient's condition and patients who have become resistant to primary treatment should consider transition to palliative care, except patients with favourable prognosis [9]. Reportedly, chemotherapy for patients with cancer nearing death worsens quality of life (QOL) even in patients with good performance status [10]. So it is said that palliative chemotherapy is not recommended. But this report was a non-randomised cohort study with various cancer types and chemotherapy regimens, benefits of novel drugs such as molecularly targeted drugs and immune checkpoint inhibitors were not reflected. So it is hard to say whether palliative chemotherapy is effective or not. Conversely, a Phase II reports gefitinib improving PS at 79% and the overall survival of EGFR mutation-positive lung

cancer patients with extremely poor PS [11]. NCCN guideline ver 1.2019 Occult primary [12] suggests specialised approaches for all patients with disseminated metastases, for examples targeted therapies or pathological profile. Palliative chemotherapy can be given without lowering QOL by introducing specialised approaches. Pazopanib, a multi-targeted tyrosine kinase inhibitor of vascular endothelial growth factor receptor (VEGFR), platelet-derived growth factor receptor and c-kit tyrosine, has single-agent activity in patients with advanced non-adipocytic Soft-Tissue Sarcoma (STS). Pazopanib for treating STS was successfully demonstrated in a multicenter Phase 3 trial conducted by the European Organization for Research and Treatment of Cancer (EORTC), EORTC 62072—PALETTE study [13]. Wherein the overall survival was 12.5 months with pazopanib versus 10.7 months with placebo. The most common adverse events were fatigue, diarrhoea, nausea and hypertension, but these are controllable. Vascular-endothelial Growth Factor (VEGF) antibody bevacizumab use is associated with an increased risk of gastrointestinal (GI) perforation, but the incidence and risk of GI perforation associated with vascular VEGF tyrosine-kinase inhibitors (VEGFR-TKIs) did not significantly increase the risk of GI perforation [14]. In this case, cytotoxic chemotherapy was more likely to cause a decrease in PS and QOL, so pazopanib was used as a therapeutic agent. No reports exist on pazopanib administration to patients with CUPs. We experienced a case of CUPs that showed relief of symptoms with late line palliative chemotherapy by specialised approaches based on the reconsideration of pathological profile. There are few reports that late line Palliative chemotherapy is effective and relieve symptoms of CUPs.

## 4. Conclusion

Taxanes and platinum-based regimens are commonly used in the first-line treatment of CUPs, but there is no specific regimen for after second-line treatment. In general, late line chemotherapy is not recommended, but we experienced a rare case of CUPs with disseminated disease that showed improvement with fifth-line palliative chemotherapy by specialised approaches based on the reconsideration of histologic type of cancer. Treatments with palliative chemotherapy based on pathological profile may relieve symptoms of CUPs even if it was late line.

## Conflict of Interest

The authors declare that they have no competing interests.

## References

- [1] Culine S. Prognostic factors in unknown primary cancer. *Semin Oncol* 2009; 36: 60-64.
- [2] Thomassen I, Verhoeven RH, van Gestel YR, et al. Population-based incidence, treatment and survival of patients with peritoneal metastases of unknown origin. *Eur J Cancer* 2014; 50: 50-56.
- [3] K. Fizazi, F. A. Greco, N. Pavlidis, et al. Cancers of unknown primary site: ESMO Clinical Practice Guidelines for diagnosis, treatment and follow-up. *Ann Oncol* 2015; 26 Suppl 5: v133–138.
- [4] Hainsworth JD, Johnson DH, Greco FA. Cisplatin-based combination chemotherapy in the treatment of poorly differentiated carcinoma and poorly differentiated adenocarcinoma of unknown primary site: results of a 12-year experience. *J Clin Oncol* 1992; 10: 912-922.
- [5] Van der Gaast A, Verweij J, Henzen-Logmans SC, et al. Carcinoma of unknown primary: identification of a treatable subset? *Ann Oncol* 1990; 1: 119-122.
- [6] Kari Hemminki, Jianguang Ji, Jan Sundquist, et al. Familial risks in cancer of unknown primary: tracking the primary sites. *J Clin Oncol* 2011; 29 (4): 435-40.
- [7] Toussaint E, Bahel-Ball E, Vekemans M, et al. Causes of fever in cancer. *Support Care Cancer*. 2006; 14 (7): 763-9.
- [8] Chang JC. Neoplastic fever. A Proposal for diagnosis. *Arch Intern Med*. 1989; 149: 1728-30.
- [9] Japanese Society of Medical Oncology the Practical Guideline for Carcinoma of Unknown Primary, 2nd Edition, Tokyo, 2018; 62-63.
- [10] Prigerson HG, Bao Y, Shah MA, et al. Chemotherapy Use, Performance Status, and Quality of Life at the End of Life. *JAMA Oncol* 2015; 1 (6): 778-84.
- [11] Inoue A, Kobayashi K, Usui K, et al. First-line gefitinib for patients with advanced non-small-cell lung cancer harboring epidermal growth factor receptor mutations without indication for chemotherapy. *J Clin Oncol* 2009; 27 (9): 1394-400.
- [12] <https://www.nccn.org/professionals/physiangls/pdf/occult.pdf>.
- [13] van der Graaf WT, Blay JY, Chawla SP, et al. Pazopanib for metastatic soft-tissue sarcoma (PALETTE): a randomised, double-blind, placebo-controlled phase 3 trial. *Lancet* 2012; 379 (9829): 1879-86.
- [14] Qi WX, Sun YJ, Tang LN, et al. Risk of gastrointestinal perforation in cancer patients treated with vascular endothelial growth factor receptor tyrosine kinase inhibitors: a systematic review and meta-analysis. *Crit Rev Oncol Hematol*. 2014; 89 (3): 394-403.