

# Sentinel Lymph Node Biopsy Efficacy in Breast Cancer: A 4-year Experience Report

Paola Iturralde-Rosas Priego, Javier Gomezpedroso-Rea, Miguel Angel Mancera-Resendiz, Daniela Stuhlt-Lopez\*, Manuel Ubiergo-Garcia

Gynecologic and Breast Private Group, Hospital Angeles Pedregal, Mexico City, Mexico

## Email address:

[dra.stuht@gmail.com](mailto:dra.stuht@gmail.com) (D. Stuhlt-Lopez)

\*Corresponding author

## To cite this article:

Paola Iturralde-Rosas Priego, Javier Gomezpedroso-Rea, Miguel Angel Mancera-Resendiz, Daniela Stuhlt-Lopez, Manuel Ubiergo-Garcia. Sentinel Lymph Node Biopsy Efficacy in Breast Cancer: A 4-year Experience Report. *Journal of Cancer Treatment and Research*. Vol. 10, No. 1, 2022, pp. 8-12. doi: 10.11648/j.jctr.20221001.12

**Received:** December 3, 2021; **Accepted:** December 30, 2021; **Published:** April 9, 2022

**Abstract:** Sentinel lymph node biopsy has been one of the most important advances in oncologic surgery, especially in breast cancer, since it decreases the high morbidity associated with radical axillary dissection, and allows treatment personalization. The staging of axillary nodes in breast cancer is fundamental as it is a prognostic indicator and determines the need for adjuvant therapy. Sentinel lymph node is detected by injecting a radioisotope and dye through the periareolar area that consequently travels through mammary glands to axillary lymph nodes. We conducted a retrospective study that included 57 women with a histopathological diagnosis of breast cancer, and underwent sentinel node biopsy. Transoperative pathology analysis reported metastases in 24% of the patients, requiring radical axillary dissection. Sensitivity was 97%, and specificity was 85%, reflecting high efficacy of the sentinel lymph node biopsy, and thus benefitting patients by decreasing morbidity. Sentinel node biopsy is the standard procedure for correct staging of patients with early breast cancer, and no clinical evidence of lymph node involvement. Further, it decreases morbidity in these patients by preventing radical axillary dissection, a previously standard approach, without compromising the diagnosis and hence, the prognosis of the patients. We demonstrated that with the correct technique for sentinel lymph node biopsy, the prognosis for patients is much better than for those patients that undergo radical axillary dissection.

**Keywords:** Sentinel Node Biopsy, Breast Cancer, Lymph Node Metastasis

## 1. Introduction

Described by Donald Morton and Alistair Cochran in 1992, the Sentinel Node (SN) biopsy is undoubtedly one of the most relevant surgical innovations in oncology surgery in recent times. It is defined as the first lymph node or group of lymph nodes to receive drainage of malignant cells from a given anatomical region. The information obtained from this procedure has fundamentally changed our knowledge and the principles on lymphatic spread of malignant tumors [1].

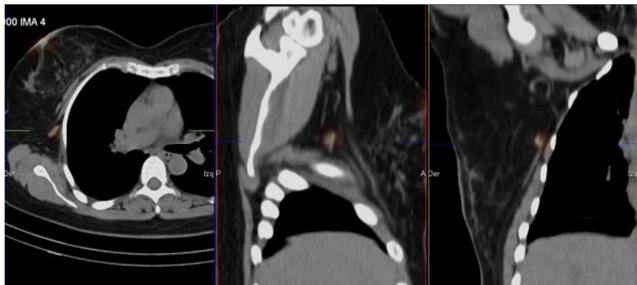
Dissection of a sentinel node has led to more accurate staging of breast cancer, and its histopathology is a prognostic factor in terms of recurrence and survival. This technique has a low false-negative rate, approximately 7%, and high sensitivity, ranging from 96-99% in the detection of

metastases [2].

In 98% of breast cancer cases, lymph node invasion is sequential and orderly, but the initially compromised node – the sentinel node – is readily available for timely biopsy. The second and third-level nodes or those under the pectoralis minor muscle subsequently become affected. Staging of axillary nodes in breast cancer remains a most important prognostic indicator, particularly in determining whether or not to administer adjuvant therapy; the sentinel node, therefore, allows us to assess the presence of axillary metastases without the morbidity associated with radical axillary dissection (RAD).

The procedure is technically relatively simple. A dye, such as patent blue or methylene blue and a radioisotope, are injected in the peri-areolar or intra-tumoral area – in case it is palpable – at least 15 minutes before the surgical procedure;

a light massage promotes the dye's and the radioisotope's dispersal through the lymphatic ducts and nodes. These markers are taken up by the tumor and transported through the lymphatic system of the mammary gland to the axillary nodes. The first lymph node refers to the one that captures the greatest amount of the dye and is located with a gamma-probe that measures the radiation emitted and indicates the location to perform the lymph node excision that will be histopathologically studied [3].

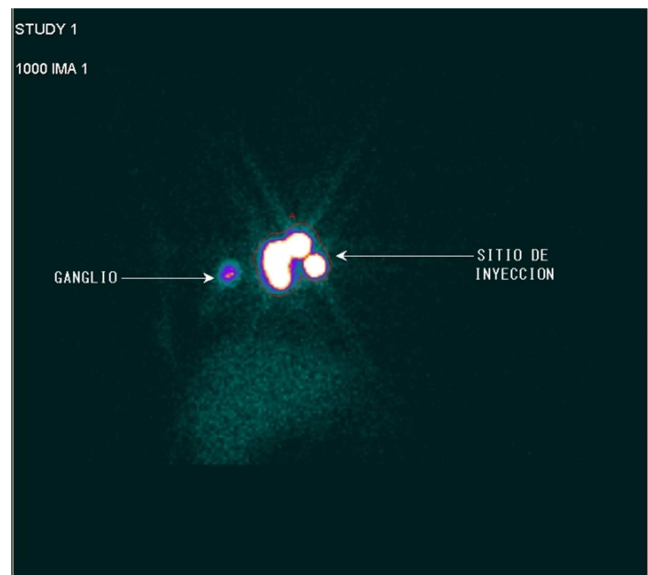


**Figure 1.** SPECT-CT image for anatomical localization of right sentinel lymph node.

As previously mentioned, the sentinel node biopsy has radically transformed the surgical management of early-stage breast cancer and is currently the initial approach in these patients. There are lines of research that continue to be explored, focusing on its usefulness in patients who have received neoadjuvant therapy, the host's response to the tumor, and the need for better parameters in the diagnosis of lymphatic metastases.

The sentinel node biopsy in breast cancer is indicated in patients with early stages, T1 & T2, with an infiltrating component, and clinically negative axillary nodes. Women

with carcinoma *in situ* who will undergo mastectomy are candidates for this procedure since lymphatic channels will be interrupted during mastectomy. Other indications are ductal carcinoma *in situ* with wide resection, or the use of an oncoplastic technique that could also compromise lymphatic channels flow. Additionally, it is used in patients with ipsilateral recurrence after having received conservative treatment, or in post-mastectomy recurrences. In patients with inflammatory carcinoma and patients with clinically positive axillary nodes in whom radical axillary dissection is indicated from the outset, sentinel node biopsy is absolutely contraindicated [4].



**Figure 2.** Right sentinel node located after dye and radioisotope application.

**Table 1.** Indications and contraindications for sentinel lymph node biopsy according to ASCO guidelines\*.

Indications	Contraindications
1. Infiltrative carcinomas in early stages with no data of axillary pathology (clinical, imaging).	1. Preoperative verification of axillary lymph node involvement either by clinical, imaging or even cytology
2. Intraductal carcinoma <i>in situ</i> with scheduled mastectomy.	2. Inflammatory carcinoma
	3. Previous axillary radiotherapy at a dose of 50Gy.
	4. Advanced carcinoma (T3 -T4)
	5. Pregnancy

\* Modified from ASCO 2016 Guidelines for Early-Stage Breast Cancer [5].

The aim of this report is to compare the histopathology results obtained in the transoperative period if judged to be positive for metastasis, with the definitive histopathological result, and analyze the concordance between both pathology studies.

## 2. Material and Methods

A comparative, linear, and retrospective review was conducted in 57 female patients at the High Specialty Gynecological and Breast Group in Mexico City, with a diagnosis of breast cancer, between January 2015 and December 2018. In this analysis, we included all patients with a diagnosis of breast cancer established histopathologically, with clinically negative lymphatic sites, and who underwent sentinel lymph node biopsy and transoperative pathology study

of the sample. All our patients received an injection under the areolar plexus with blue patent and rhenium (radioisotope) 2 hours prior to surgery, allowing the tracers to enter through the lymphatic system from the breast to the axillary lymph nodes. Additionally, images from SPECT-CT were taken to visualize the anatomic localization of the sentinel lymph node. To be included in this study, the patients required a complete medical chart and the histopathology reports, both the transoperative and the definite reports. It should be noted that all these studies were performed by the same group of pathologists, thus minimizing inter-observer bias.

## 3. Results

The study analyzed a total of 57 patients, aged between 38

and 80 years, with an average age of  $56.3 \pm 11.1$  years, and a median age of 54 years.

When evaluating the mammographies, 8 (14.1%) were classified as BIRADS 4A, 11 (19.3%) as BIRADS 4B, 11 (19.3%) as BIRADS 4C, and 27 (47.3%) as BIRADS 5.

Excisional biopsy was performed in 8 (14.1%) patients, while the remaining 49 (85.9%) underwent Tru-Cut needle biopsy. Histologically, 3 (5.3%) cases had ductal carcinoma *in situ*, while infiltrating ductal carcinoma was reported in 45 (78.9%), 4 (7.0%) cases presented infiltrating lobular carcinoma, there was 1 (1.7%) mucinous carcinoma, and 2 (3.5%) patients had intraductal carcinoma of the comedo-carcinoma type. Forty-nine percent of the tumors (49.1%) (28) were on the right side, 47.3% (27) were on the left, and only 3.5% (2) were bilateral.

The final pathology reports referred that 3.5% (2) of the tumors were ductal *in situ*, 77.1% (44) were infiltrating ductal carcinomas, 7.0% (4) were infiltrating lobular, 3.5% (2) were ductal *in situ* and infiltrating, 1.7% (1) were lobular *in situ*, 1.7% (1) were lobular *in situ* and infiltrating, 1.7% (1) were of the mucinous type, 1.7% (1) were ductal *in situ*, infiltrating ductal and lobular, and only 1.7% (1) presented a mixed pattern of infiltrating ductal with comedo-carcinoma.

All 57 patients included in this study underwent sentinel

lymph node biopsy and reported that 24% (14) of patients were positive for metastasis during the transoperative study, and 76% (43) were negative for metastasis. Invasions greater than or equal to 2mm were considered a lymph node metastasis.

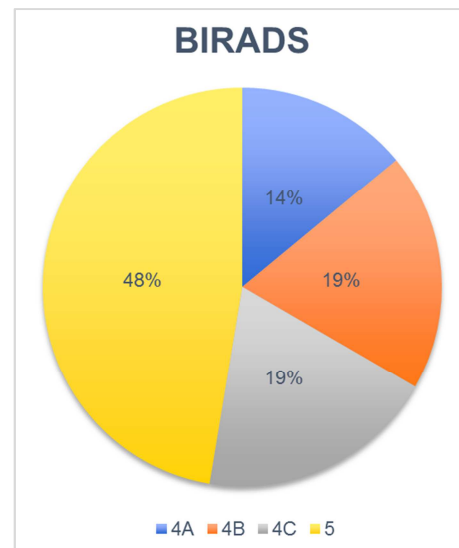


Figure 3. BIRADS distribution in mammography.

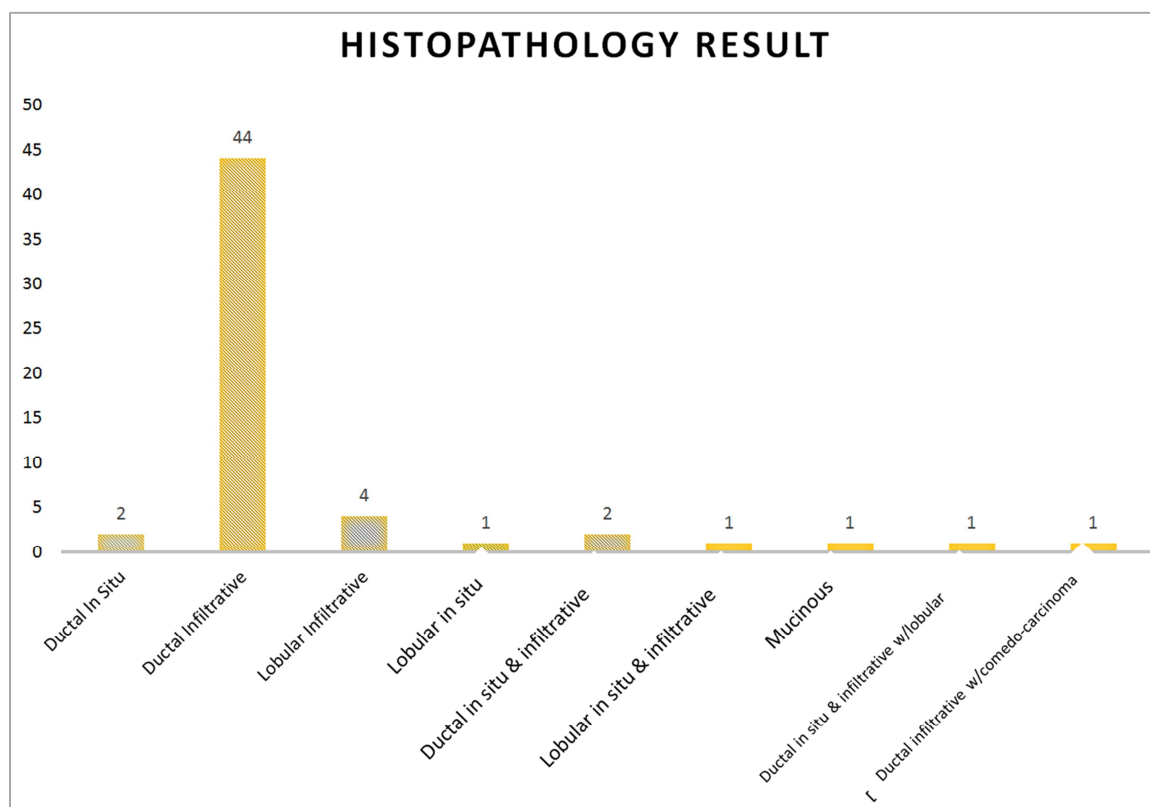
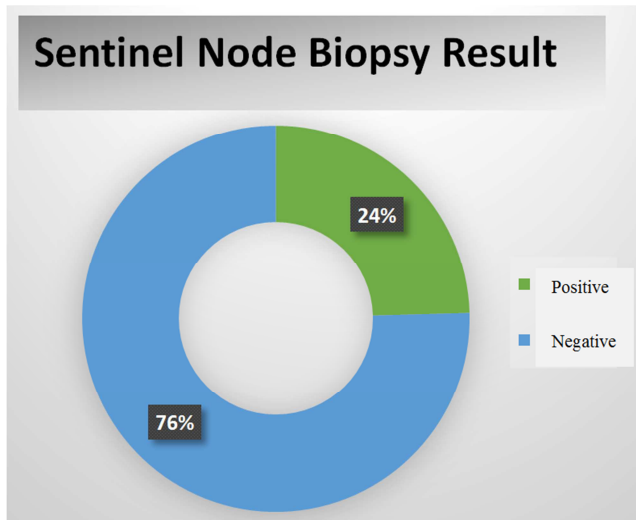


Figure 4. Biopsy histopathology results.

When the final histopathologic study was compared with the transoperative study of the sentinel lymph node, among 14 cases reported as positive in the intraoperative study, only one was reported as negative in the definitive study. As to the

43 cases of sentinel lymph nodes reported as negative, 2 were positive in the definitive study. These results reflect a sensitivity of 86%, and a 97% specificity for the sentinel lymph node technique. The percentage of false negatives was

14%, while the percentage of false positives was 3%, yielding a positive predictive value of 92%, and a negative predictive value of 95%.



**Figure 5.** Sentinel node biopsy results.

## 4. Discussion

Sentinel node biopsy is the standard procedure for correct staging of patients with early breast cancer, and no clinical evidence of lymph node involvement. Further, it decreases morbidity in these patients by preventing radical axillary dissection, a previously standard approach, without compromising the diagnosis and hence, the prognosis of the patients. [6]

The world literature has reported that 5% to 15% false-negative results may occur. Our sensitivity and specificity findings for the sentinel node technique were 97% and 86%, respectively; there were 14% false-negative results, all in all significantly decreasing morbidity in our patients, and promoting better survival and long-term prognoses. [7, 8]

The biopsy's high sensitivity detected in our population may result from the fact that all the procedures were performed by the same group of experts, who have been performing the procedure since 2002; in our center, the learning curve has reached its peak, and all the professionals are considered experts in each of their areas. Consequently, this significantly decreases the rate of false-negative results with this procedure.

The ASCO (American Society of Clinical Oncology) recommendations, updated in 2016 (see Table), reserve the use of radical axillary dissection to patients whose tumor is larger than 5cm, and if they harbor several metastatic axillary nodes or distant metastases. However, if only one or two metastasis-positive axillary nodes are present, axillary dissection can be avoided, since radiotherapy can be used over the entire affected field. ASCO guidelines also encourage the use of the sentinel node technique for the benefit of patients with early-stage breast cancer.

In recent studies it has been reported that there is no difference in locoregional recurrence for patients with

positive sentinel lymph node randomized to either axillary lymph node dissection or sentinel lymph node biopsy alone. [9, 10]

Further, long-term locoregional recurrence results demonstrated that at a median follow-up of 9.25 years, there was no statistically significant difference in local recurrence-free survival. [11] The cumulative incidence of nodal recurrences at 10 years was 0.5% in the axillary lymph node dissection arm and 1.5% in the sentinel lymph node biopsy alone arm. Ten-year cumulative locoregional recurrence was 6.2% with axillary lymph node dissection and 5.3% with sentinel lymph node biopsy alone. [12, 13]

Furthermore, metastases in ductal carcinoma in situ are rare and often limited in extent, but it is highly recommended and supported by published guidelines to evaluate the sentinel lymph node in these patients, despite the rarity of nodal involvement. [14]

The development of clinical guidelines for the management of the axilla in patients with breast cancer is a work in progress. Garcia-Etienne et al. discussed and determined that axillary lymph node dissection may be avoided in patients with a clinically negative axilla who have micro or macrometastasis to no more than two sentinel lymph nodes, who are at least 40 years old, with lesions not larger than 3 cm, who have not received neoadjuvant chemotherapy and have planned breast conservation surgery with whole breast radiotherapy. Cases with tumors larger than 3 cm and micrometastasis to the sentinel lymph node and cases with gross (>2 mm) extracapsular extension in sentinel lymph node are evaluated on individual basis for completion axillary lymph node dissection, axillary radiotherapy or omission of both. [15]

Additionally, the ACOSOG Z0011 clinical study, with a 10-year follow-up, corroborated that the survival rate in patients in whom the sentinel node technique was performed in association with some form of adjuvant therapy, was similar to that in patients who underwent radical axillary dissection. This same recommendation is supported by the National Comprehensive Cancer Network (NCCN) guidelines for breast cancer, updated in September 2019.

## 5. Conclusion

We conclude that sentinel node biopsy promotes a decrease in morbidity rates, and survival rates are similar to conventional breast cancer surgical management techniques. The accurate technique for the sentinel lymph node, is one of the most important advances in the treatment for patients with breast cancer.

Further, patients in whom a sentinel node biopsy was obtained, showed fewer side-effects during the postoperative period, thus decreasing the immediate morbidity associated with radical axillary dissection, such as surgical site infection, lymphedema in the arm and/or shoulder, pain in the arm and shoulder, and paresthesia or dysesthesia in the arm, all adversely affecting the patients' quality of life.

## Disclosure

All of the authors do not have any possible conflicts of interest.

## References

- [1] Gallegos-Hernández JF. El ganglio centinela. *Rev Mex Anesthesiol.* 2007; 30, Supl. 1 abr-jun.
- [2] Nielsen Moody A, Bull J, Culpan A.-M., Munyombwe T, Sharma N, Whitaker M, Wolstenhulme S. (2017). Preoperative sentinel lymph node identification, biopsy and localisation using contrast enhanced ultrasound (CEUS) in patients with breast cancer: a systematic review and meta-analysis. *Clin Radiol.* 2017; 72 (11): 959–971. doi: 10.1016/j.crad.2017.06.121.
- [3] Bernet L, *et al.* Consenso sobre la biopsia selectiva del ganglio centinela en el cáncer de mama. Revisión 2013 de la Sociedad Española de Senología y Patología Mamaria. *Rev Esp Patol.* 2014. <http://dx.doi.org/10.1016/j.patol.2013.11.001>
- [4] Manca G, Rubello D, Tardelli E, Giammarile F, Mazzarri S, Boni G, Colletti PM (2016). Sentinel Lymph Node Biopsy in Breast Cancer. *Clin Nucl Med* 2016; 41 (2): 126–133. doi: 10.1097/rlu.0000000000000985.
- [5] Lyman GH, Somerfield MR, Bosserman LD, Perkins CL, Weaver DL, Giuliano AE. Sentinel Lymph Node Biopsy for Patients with Early-Stage Breast Cancer: American Society of Clinical Oncology Clinical Practice Guideline Update. *J Clin Oncol* 2016; 35: 561-564.
- [6] Veronesi U, Paganelli G, Viale G, Luini A, Zurrada S, Galimberti V, Gennari R. A Randomized Comparison of Sentinel-Node Biopsy with Routine Axillary Dissection in Breast Cancer. *N Engl J Med* 2003; 349 (6), 546–553. doi: 10.1056/nejmoa012782.
- [7] Giuliano AE, Ballman KV, McCall L, Beitsch PD, Brennan MB, Kelemen PR, Morrow M. Effect of Axillary Dissection vs No Axillary Dissection on 10-Year Overall Survival Among Women with Invasive Breast Cancer and Sentinel Node Metastasis. *JAMA* 2017; 318 (10), 918. doi: 10.1001/jama.2017.11470.
- [8] Duraes M, Guillot E, Seror J, Pouget N, Rouzier R. Ganglion sentinelle et chimiothérapie néoadjuvante dans le cancer du sein. *Bull Cancer* 2017; 104 (10): 92–901. doi: 10.1016/j.bulcan.2017.08.003.
- [9] Munck F, Clausen E W, Balslev E, Kroman N, Tvedskov TF, Holm-Rasmussen EV. Multicentre study of the risk of invasive cancer and use of sentinel node biopsy in women with a preoperative diagnosis of ductal carcinoma in situ. *Br J Surg* 2019 doi: 10.1002/bjs.11377.
- [10] Morrow M, Jagsi R, McLeod M C, Shumway D, Katz S J. Surgeon Attitudes Toward the Omission of Axillary Dissection in Early Breast Cancer. *JAMA Oncol.* 2018. doi: 10.1001/jamaoncol.2018.1908.
- [11] Giuliano A E. Axillary Dissection vs No Axillary Dissection in Women with Invasive Breast Cancer and Sentinel Node Metastasis. *JAMA*, 2011; 305 (6), 569. doi: 10.1001/jama.2011.90.
- [12] NCCN Clinical Practice Guidelines in Oncology. Breast cancer. Septiembre 2019.
- [13] Veronesi, P., & Corso, G. (2019). Standard and controversies in sentinel node in breast cancer patients. *The Breast*, 48, S53–S56. doi: 10.1016/s0960-9776(19)31124-5.
- [14] Fan, B., Pardo, J. A., Serres, S., Alapati, A. C., Szewczyk, J., Mele, A., & James, T. A. (2020). Role of Sentinel Lymph Node Biopsy in Microinvasive Breast Cancer. *Annals of Surgical Oncology*. doi: 10.1245/s10434-020-08606-3.
- [15] Garcia-Etienne, C. A., Ferrari, A., Della Valle, A., Lucioni, M., Ferraris, E., Di Giulio, G., ... Sgarella, A. (2019). Management of the axilla in patients with breast cancer and positive sentinel lymph node biopsy: An evidence-based update in a European breast center. *European Journal of Surgical Oncology*. doi: 10.1016/j.ejso.2019.08.013.